



Epistaxis: an update on current management

L E R Pope and C G L Hobbs

Postgrad. Med. J. 2005;81;309-314
doi:10.1136/pgmj.2004.025007

Updated information and services can be found at:

<http://pmj.bmjournals.com/cgi/content/full/81/955/309>

These include:

Rapid responses

You can respond to this article at:

<http://pmj.bmjournals.com/cgi/eletter-submit/81/955/309>

Email alerting service

Receive free email alerts when new articles cite this article - sign up in the box at the top right corner of the article

Topic collections

Articles on similar topics can be found in the following collections

[Otolaryngology/ENT](#) (140 articles)

Notes

To order reprints of this article go to:

<http://www.bmjournals.com/cgi/reprintform>

To subscribe to *Postgraduate Medical Journal* go to:

<http://www.bmjournals.com/subscriptions/>

REVIEW

Epistaxis: an update on current management

L E R Pope, C G L Hobbs

Postgrad Med J 2005;81:309–314. doi: 10.1136/pgmj.2004.025007

Epistaxis is one of the commonest ENT emergencies. Although most patients can be treated within an accident and emergency setting, some are complex and may require specialist intervention. There are multiple risk factors for the development of epistaxis and it can affect any age group, but it is the elderly population with their associated morbidity who often require more intensive treatment and subsequent admission. Treatment strategies have been broadly similar for decades. However, with the evolution of endoscopic technology, new ways of actively managing epistaxis are now available. Recent evidence suggests that this, combined with the use of stepwise management plans, should limit patient complications and the need for admission. This review discusses the various treatment options and integrates the traditional methods with modern techniques.

Epistaxis, whether spontaneous or otherwise, is experienced by up to 60% of people in their lifetime, with 6% requiring medical attention.¹ Although our understanding of this condition has improved considerably, the principle of packing the nose for a nosebleed has changed little since Hippocrates used sheep's wool on pugilistic noses in ancient Greece.

EPIDEMIOLOGY

The incidence of epistaxis varies greatly with age. There is a bimodal distribution with peaks in children and young adults and the older adult (45–65 years).² Anecdotal evidence suggests that certain stereotypical groups are more prone (for example, elderly women or young boys).

ANATOMY

One of the primary functions of the nose is to warm and humidify air. It therefore has a profuse blood supply arising from both the internal and external carotid arteries.

Epistaxis is normally classified into anterior or posterior, but it can also be classed as superior or inferior depending on the carotid supply. Broadly, the internal carotid (via the ethmoidal arteries) supplies the region above the middle turbinate while the remaining areas are supplied by branches of the external carotid artery. This includes the sphenopalatine artery, which supplies most of the septum and turbinates on the lateral wall. The interface between the two carotid systems varies in position according to the pressure in each one. There is also crossover between the right and left arterial systems,

which can result in persistent nasal bleeding despite unilateral arterial ligation.

Anterior bleeds are responsible for about 80% of epistaxis. They occur at an anastomosis called Kiesselbach's plexus on the lower part of the anterior septum known as Little's area. Posterior bleeding derives primarily from the posterior septal nasal artery (a branch of the sphenopalatine artery), which forms part of the Woodruff plexus.

AETIOLOGY

The aetiology of epistaxis can be divided into local and general causes (box 1), however most (80%–90%) are actually idiopathic. An important contributing factor, in addition to the prominent vascularity and dual blood supply to the nose, is that blood vessels within the nasal mucosa run superficially and are therefore comparatively unprotected. In most cases, it is damage to this mucosa and to vessel walls that results in bleeding. Spontaneous rupture of blood vessels may occur occasionally, such as during extreme valsalva when weightlifting. Although uncommon, it is important to exclude neoplasia as a cause for unexplained recurrent unilateral epistaxis.

MANAGEMENT

The traditional management of acute epistaxis entails identification of the bleeding point by using a head mirror or other light source. If a bleeding point is localised, then chemical or electrocautery is performed. If unsuccessful, further management takes a stepwise approach—initially anterior packing with some form of gauze or sponge and then failing this, more advanced techniques such as compressive balloons or posterior packing. Finally, arterial ligation or embolisation can be used to stem intractable bleeds. Figure 1 outlines a suggested management plan.

Resuscitation

Epistaxis is a potential life threatening event. All patients who are actively bleeding need full assessment and resuscitation if necessary. The clinical state of an elderly patient may deteriorate rapidly so aggressive resuscitation is vital. Universal precautions should be worn before starting any treatment including a facemask and eye protection. Vital signs must be monitored regularly. A full blood count should be taken and blood group and saved. Studies have shown that routine clotting studies need to be performed only if there is a suspected clotting diathesis or the patient is anticoagulated.³ Fluid management should be instigated if signs of hypovolaemia are present or admission is required. During resuscitation, bleeding can commonly be controlled by digital pressure over the lower soft cartilaginous part of the nose. This is often best performed by

See end of article for authors' affiliations

Correspondence to:
Mr C G L Hobbs,
Department of
Otolaryngology and Head
and Neck Surgery, St
Michael's Hospital,
Southwell Street, Bristol
BS2 8EG, UK; chris.hobbs@doctors.org.uk

Submitted 4 June 2004
Accepted
14 September 2004

Box 1 Causes of epistaxis**Local**

- Idiopathic
- Trauma
 - Nose picking
 - Facial injury
 - Foreign body
- Inflammation
 - Infection
 - Allergic rhinosinusitis
 - Nasal polyps
- Neoplasia
 - Benign (for example, juvenile angiofibroma)
 - Malignant (for example, squamous cell carcinoma)
- Vascular
 - Congenital (for example, hereditary haemorrhagic telangiectasia)
 - Acquired (for example, Wegener's granulomatosis)
- Iatrogenic
 - Surgery (for example, ENT/maxillofacial/ophthalmic)
 - Nasal apparatus (for example, nasogastric tube)
- Structural
 - Septal spurs or deviation
 - Septal perforations
- Drugs
 - Nasal sprays (for example, topical decongestants)
 - Abuse (for example, cocaine)

General

- Haematological
 - Coagulopathies (for example, haemophilia)
 - Thrombocytopenia (for example, leukaemia)
 - Platelet dysfunction (for example, Von Willebrand's disease)
- Environmental
 - Temperature
 - Humidity
 - Altitude
- Drugs
 - Anticoagulants (for example, heparin, warfarin)
 - Antiplatelet (for example, aspirin, clopidogrel)
- Organ failure
 - Uraemia
 - Liver (for example, cirrhosis)
- Other
 - Atherosclerosis/hypertension
 - Alcohol

an assistant (nurse or healthcare assistant) and can be improved by a cold compress or the patient sucking on ice. Leaning the patient forward will decrease blood flow through

the nasopharynx, which is less uncomfortable for the patient and will help to reduce swallowing of blood and its subsequent nausea.

Nasal preparation

Good nasal preparation is critical to elucidate and treat the cause of epistaxis. The nasal cavity is often obscured by clots. Thus immediately before examination a forceful blow by the patient through the nose can clear these clots. Although this action may restart bleeding it will enable improved access for anaesthetic. A precautionary view of the cavity should be undertaken by anterior rhinoscopy using a Thudicum's speculum; this will enable stubborn clots to be evacuated by suction and permit initial assessment of the bleeding point.

Local anaesthetic, ideally including a vasoconstrictor, should be applied to the nasal mucosa over Little's area (box 2). The application method varies on the preparation, but most entail either a solution applied on cotton wool or as a nasal spray. Time should be allowed for the anaesthetic to work.

Generally, systemic analgesia is not necessary when inspecting or packing the nose, although mild sedation (with a small dose of diazepam) is often used in hypertensive or anxious patients. Once adequate local anaesthesia is achieved, the nasal cavity can be examined and treatment instigated to stem the haemorrhage. Little's area is viewed first.

Cautery

Chemical cautery is achieved by using a silver nitrate stick (75% silver nitrate, 25% potassium nitrate BP w/w) that reacts to the mucosal lining to produce local chemical damage. The technique entails applying the stick to the bleeding point with firm pressure for 5–10 seconds. The effect varies with concentration and exposure. Feeding vessels can also be cauterised to limit recurrence. Careful removal of excess silver nitrate helps prevent staining of the vestibule or upper lip. If staining does occur, it should be neutralised immediately by applying normal saline. Only one side of the septum should be cauterised, as there is a small risk of septal perforation resulting from decreased vascularisation to the septal cartilage. For this reason, we suggest a four to six week interval between cautery treatments.

Electrocautery is usually performed in clinic by otolaryngologists under local anaesthetic; it consists of an electrical circuit that heats up a metal loop. With this technique thermal energy seals the bleeding vessel by radiation, not by direct contact. A potential complication is heat damage to the anterior nares and inferior turbinate. This risk can be reduced by using a large aural speculum under microscopic examination.

Anterior packing

The nose should be packed if bleeding continues despite cautery or if no obvious bleeding is seen. There are many forms of anterior nasal packing although nasal sponges have become predominant as they offer a simple and effective mechanism for applying pressure to the bleeding vessel.

Nasal tampons

There are several types available.

Merocel is made of polyvinyl alcohol, a compressed foam polymer that is inserted into the nose (fig 2) and expanded by application of water. This causes the tampon to swell and fill the nasal cavity, applying pressure over the bleeding point. It may also allow clotting factors to localise and reach a critical level, thereby facilitating coagulation. Merocels are easy to insert within a casualty setting and require minimal training. They are effective in 85% of cases, with no difference between the success rates when compared with traditional ribbon gauze.⁴

Rapid Rhino is an example of a carboxymethylcellulose pack. This is a hydrocolloid material, which acts as a platelet aggregator and also forms a lubricant on contact with water.

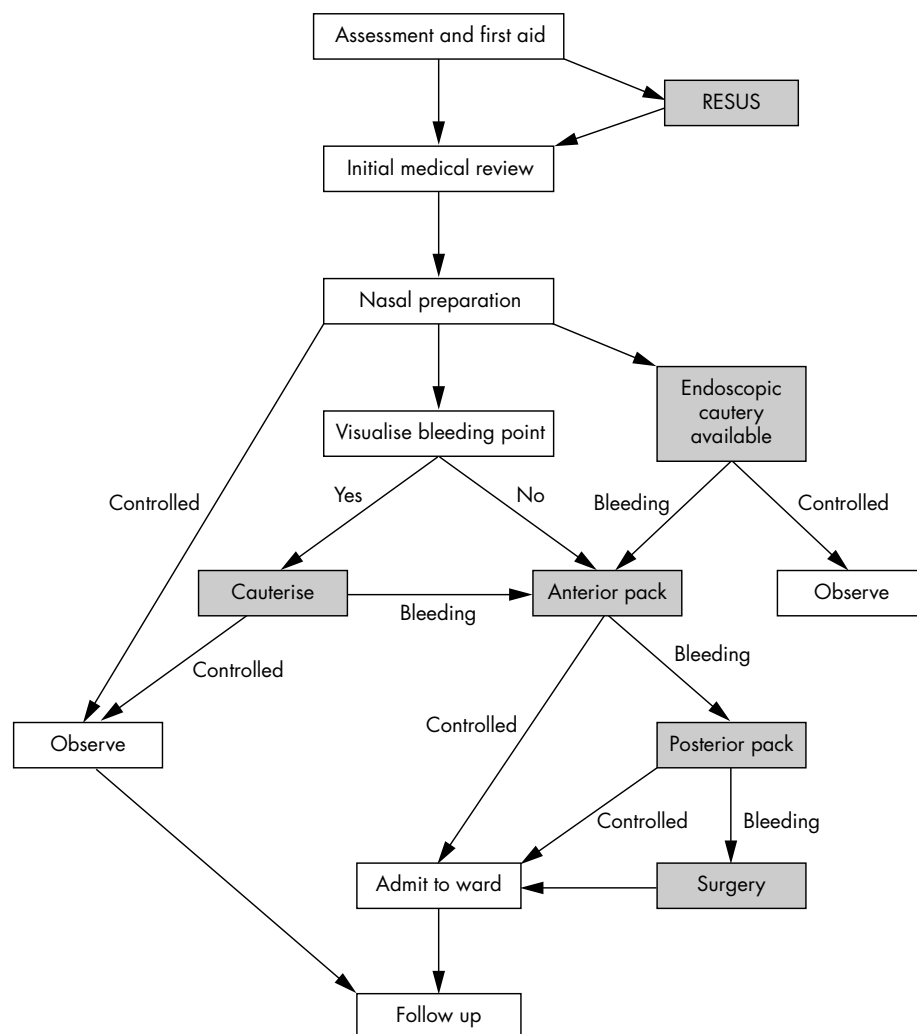


Figure 1 Epistaxis management protocol.

Unlike Merocel, it has a cuff that is inflated by air and the hydrocolloid or *Gel-Knit* is supposed to preserve newly formed clot during removal.

Formal anterior packing

If nasal tampon packing fails to stem epistaxis, then one should consider formal packing with ribbon gauze. Again, there are many pre-prepared packs on the market, but the most common are Vaseline or bismuth-iodoform paraffin paste impregnated packs. These packs should be inserted under direct vision into a locally anaesthetised nasal cavity. After nasal packing, the patient is examined for ongoing bleeding through the pack, from the contralateral nares or posteriorly. This is done using a tongue depressor to obtain a good view of the oropharynx. If any bleeding is witnessed, packing of the other side should be considered before removal of the already inserted pack. This

may increase the tamponade pressure over the septum and stop the bleeding. Because of the risks associated with nasal packing (box 3), most patients are admitted to the ward. Some units will discharge a haemodynamically stable person home with packing in situ, for review in 24–48 hours, although this is controversial because of the potential complications. If packs are left in for more than 48 hours, then antibiotics should be started to prevent toxic shock syndrome. Packs are usually removed within three days.

Posterior packing

Anterior packing is often insufficient to control vessels bleeding from the posterior nasal cavity. These bleeds can be difficult to treat and may require either balloon insertion or a formal posterior pack.

Balloon insertion

This relies on either direct pressure or more commonly, the accumulation of blood within the nasal cavity leading to tamponade. There are several types that can be used; some have been designed especially for epistaxis management. Two of the important types are discussed.

Foley catheter

This uses a standard urinary catheter that is inserted through the anterior nares and passed back until the tip is seen in the oropharynx. It is then inflated with 3–4 ml of water or air. The catheter is pulled forward until the balloon engages the

Box 2 Common local anaesthetic preparations

- Lidocaine injection (0.5%, 1%, or 2%) with adrenaline (epinephrine) 1/200 000
- Cocaine topical solution (2% or 5%)
- Cocaine paste (10%)
- Lidocaine topical solution (5%) with 0.5 % phenylephrine (cophenylcaine)

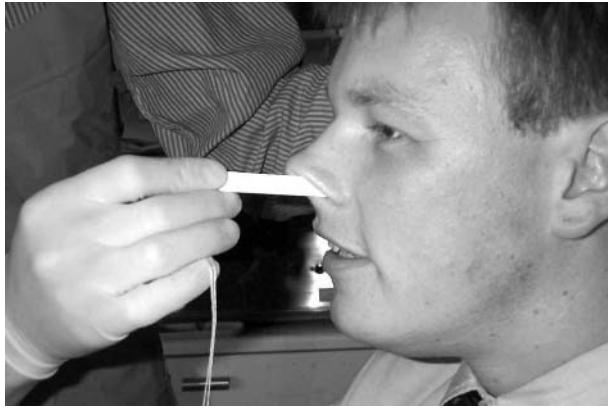

Figure 2 Correct insertion of a nasal tampon (note that the direction is along the floor of the nasal cavity).

posterior choana. The nasal cavity is then packed anteriorly with ribbon gauze or a nasal sponge. The balloon is held firmly in place with an umbilical clamp at the anterior nares. It is important in this case to protect the columella with a soft dressing, otherwise it is susceptible to pressure necrosis. Other complications include posterior displacement of the balloon with potential airway compromise, deflation in situ (which is more likely to occur with air inflation) and rupture of the balloon, which when it contains water, could result in aspiration. Recent evidence suggests that balloon rupture is more likely with the use of paraffin paste.⁹ It is important to note the Foley catheter is in fact, not licensed for nasal use.

Brighton balloon

This is specifically manufactured for the treatment of epistaxis. It has a postnasal balloon and a mobile anterior balloon that are independently inflated (fig 3). Other specialised balloons include the Simpson plug and the Epistat nasal catheter.

Formal posterior packing

In this rather uncomfortable procedure (hence it is normally performed under general anaesthetic), a gauze pad is sutured to a catheter inserted through the nose and using the catheter, is manoeuvred via the oral cavity into the nasopharynx so that it lodges against the choana. It is important to protect the columella with a dental roll to stop

Box 3 Complications of nasal packing

- Failure to stem bleeding
- Toxic shock syndrome
- Blockage of
 - nasolacrimal duct leading to epiphora
 - sinus drainage leading to acute sinusitis
 - nasal airway leading to hypoxia
- Nasovagal reflex: this reflex occurs during insertion of a pack or instrumentation of the nasal cavity. It leads to vagal stimulation, with consequent hypotension and bradycardia
- Sleep apnoea, attributable to decreased nasal air entry leading to hypoxia during somnolence
- Displacement of pack into oropharynx with risk of acute airway obstruction
- Removal may induce bleeding

pressure necrosis. The patient should always be admitted to hospital and consideration given to placing elderly patients or young children in a high dependency or intensive care environment for monitoring.

Surgery

Any bleeding that fails to stop despite an escalation of clinic room management requires surgical intervention. This includes bleeding that continues after pack removal. Before theatre, the patient needs to be haemodynamically stable. In most cases surgical management requires a general anaesthetic, although in frail elderly patients, local anaesthesia with sedation can be used. Surgical intervention can be divided into diathermy, septal surgery, or arterial ligation.

Diathermy

The localisation of a bleeding point under general anaesthetic is easier because of improved nasal access and instrumentation. The use of bipolar rather than monopolar diathermy is recommended, as there are reports of optic or oculomotor nerve damage after the use of monopolar in⁶ or close to the orbit.⁷

Septal surgery

Septal surgery is sometimes performed to allow access to the nasal cavity. As most haemorrhages occur from the septum, raising a mucoperichondral flap during septal surgery can be beneficial as this will decrease blood flow to the mucosa, which often in itself stems bleeding. Surgery is also used to correct a deviated septum or remove a septal spur, which may be the cause of epistaxis. This occurs either by altering air flow through the nose or in severe cartilage deformities, by persistent mucosal irritation.

Sphenopalatine artery ligation

In cases of ongoing haemorrhage despite the above methods, this procedure is normally attempted first. It is performed under direct rigid endoscopy and the vessel is normally clipped or coagulated using bipolar diathermy. Its success rate is reported to be better than other forms of arterial ligation probably because it is an end artery with little collateral flow.⁸

Anterior/posterior ethmoidal artery ligation

This is occasionally required for severe bleeding from the ethmoidal region and is traditionally performed via an external ethmoidectomy incision, through a subperiosteal plane on the medial orbital wall. An endoscopic technique has been described⁹ and also, more recently, an endoscopically assisted external approach.¹⁰

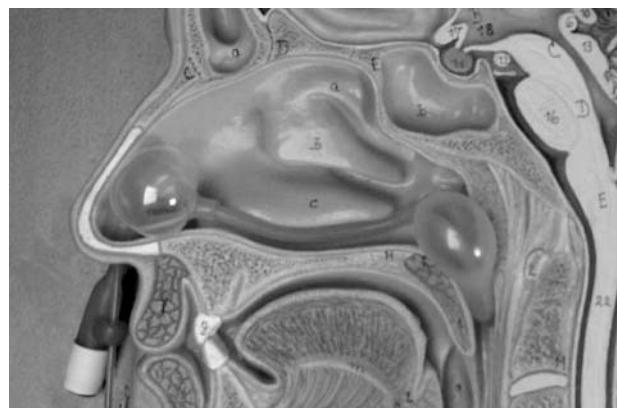


Figure 3 Sagittal view of the nasal cavity with a Brighton balloon in situ.

Maxillary artery ligation

This is rarely performed now since the introduction of endoscopic nasal surgery, but it has been shown to be effective in 87% of cases.¹¹ The approach is a modified Caldwell-Luc operation, through the posterior wall of the maxillary sinus into the pterygopalatine fossa. The maxillary vessel can be either clipped or diathermied. Complications of this include devitalised gums and teeth, sinusitis, and problematic intraoperative bleeding.

External carotid artery ligation

Ligation of the carotid artery for intractable epistaxis was first reported by Pilz in 1869 (performed on the common carotid artery in this case). It is a non-specific method of decreasing blood flow to the nose and, studies have shown a long term failure rate of 45%. This is because the nasal blood supply has marked watershed areas supplied by the contralateral external carotid.¹² In general, it should be considered a last resort, useful in profound uncontrolled haemorrhage, when the above methods fail.

OTHER MANAGEMENT OPTIONS

Angiographic embolisation

Sokoloff first undertook angiographic embolisation for epistaxis in 1972.¹³ Embolisation is routinely performed in some centres as a means of treating intractable epistaxis. The technique entails cannulation of the external carotid artery and location of the bleeding point by water soluble contrast. Coils, gel foam, and polyvinyl alcohol can then embolise the causative artery. The success rate has been reported to be as high as 87%, which is similar to arterial ligation.¹⁴ The technique's limiting factors include; lack of specialist radiologists and equipment, the inability to embolise ethmoidal arteries because of the risk of blindness, false aneurysm development at the insertion site, cerebrovascular accidents, and imaging difficulties after nasal packing. Studies have reported a complication rate of 17%–27%.¹⁵

Fibrin glue

Fibrin glue is developed from human plasma cryoprecipitate and binds itself to damaged vessels. The technique entails spraying a thin layer of glue over the bleeding site and can be repeated as needed. A recent randomised trial has reported that complications of local swelling, nasal mucosa atrophy, and excessive nasal discharge were lower than the electrocautery, silver nitrate, and nasal packing group. The rebleed rate was 15%, which is comparable to electrocautery.¹⁶

Endoscopic electrocautery

The invention of the Hopkins rod in 1960s has revolutionised nasal surgery. Only recently has this new technology been adapted for the treatment of epistaxis (fig 4).^{17–19} The nose should be prepared as described previously.

Examination of the nasal cavity is performed using a rigid Hopkin's rod endoscope (0° or 30° angle). Clots are removed using suction, which will also elicit the bleeding point. It is good practice to adopt a routine when examining the nasal cavity, viewing the septum first. On location of the bleeding point, electrocautery is used to seal the vessel. The authors recommend a bipolar cautery device with integrated suction tip to improve the field of view and increase efficiency of the cautery. Nasal packing is only instigated if the bleeding fails to cease after the procedure or if the bleeding point cannot be identified. The patient should be kept under observation for two hours and can be discharged home if no re-bleeding occurs. A recent study showed that this procedure was successful in treating 89% of patients with epistaxis with 74% not requiring admission.¹⁹ This reduction in the need for admission, added to the benefits of not inserting a pack, makes it a useful and cost effective procedure.

Hot water irrigation

The use of hot water irrigation is an alternative management strategy for posterior epistaxis. Techniques vary, but essentially a balloon catheter is used to close off the posterior choana and water at 45°C–50°C is inserted into the nasal cavity. As well as helping to clear blood clots from the nose, it probably reduces local blood flow by causing mucosal oedema.²⁰

Laser

Laser has proved to be particularly useful in cases of recurrent epistaxis, such as those occurring in hereditary haemorrhagic telangiectasia (Osler-Weber-Rendu disease). Neodymium yttrium-aluminium-garnet (Nd:YAG) laser is commonly used (via endoscopy), although the application of other lasers such as argon or carbon dioxide has also been described.²¹

FOLLOW UP

All patients with a history of severe epistaxis require a formal examination of the nasal cavity to rule out a neoplastic lesion. This can be performed before discharge or in clinic at a later date. Patients should be given a leaflet showing first aid procedures for epistaxis and simple precautions to decrease recurrence including refraining from activities that may stimulate bleeding (blowing or picking their nose, heavy lifting, strenuous exercise) and abstinence from alcohol or hot drinks that can cause vasodilatation of the nasal vessels. To limit recurrent bleeds, topical antiseptic cream (Naseptin) or petroleum jelly (Vaseline) can be prescribed, although its efficacy is questionable.²²

Patients with high blood pressure on admission need assessment by their general practitioner after discharge from hospital. Patient medication, especially anticoagulants, raise concerns in management; although a prospective study showed warfarin does not need to be stopped if its levels are within therapeutic range.²³ Aspirin medication has been shown to be independently associated with epistaxis hospitalisation.²⁴ However, cessation of aspirin therapy should be weighed up against thromboembolic complications and the time delay between stopping aspirin and the return of normal platelet function.

CONCLUSIONS

Over the past 10 years, there has been a significant expansion in the options available for the management of epistaxis. Traditional strategies like nasal packing have been supplemented by modern technology using the latest optic and electrical devices. Treatment should ideally use a systematic protocol, such as described in this review; starting with simple procedures that can be undertaken in the clinic environment and proceeding to endoscopic techniques for more difficult cases.

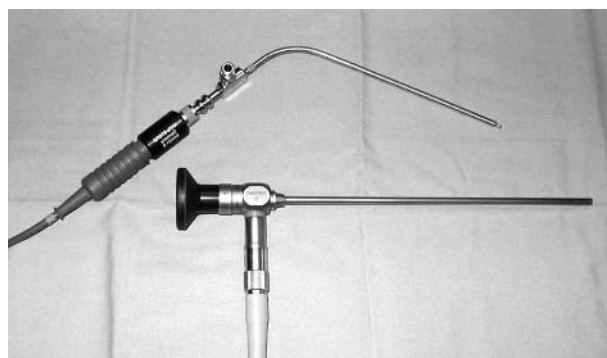

Figure 4 Endoscopic electrocautery equipment.

Key references

- Watkinson JC. Epistaxis. In: Mackay IS, Bull TR, eds. *Scott Brown's otolaryngology*. London: Butterworths, 1997:18/5-7.
- Burton M, Doree C. Interventions for recurrent idiopathic epistaxis (nosebleeds) in children. *Cochrane Library*. Issue 1. Oxford: Update Software, 2004.
- Shin EJ, Murr AH. Managing epistaxis. *Curr Opin Otolaryngol Head Neck Surg* 2000;**8**:37-42.
- Stankiewicz JA. Nasal endoscopy and control of epistaxis. *Curr Opin Otolaryngol Head Neck Surg* 2004;**12**:43-5.
- Ahmed A, Woolford TJ. Endoscopic bipolar diathermy in the management of epistaxis: an effective and cost-efficient treatment. *Clin Otolaryngol* 2003;**28**:273-275.

MULTIPLE CHOICE QUESTIONS (TRUE (T)/FALSE (F); ANSWERS AT END OF REFERENCES)

- Possible causes of epistaxis include:
 - Nasotracheal intubation
 - Disseminated intravascular coagulation (DIC)
 - Hyperthyroidism
 - Scurvy
 - Pseudogout (chondrocalcinosis)
 - The following steps are appropriate in the management of an 80 year old man with acute epistaxis:
 - Pressure should be applied to the bridge of the nose to help stop bleeding
 - After resuscitation, he should be examined in theatre under general anaesthetic
 - A full blood count should be performed
 - There is no need to check for ongoing bleeding if an anterior pack is inserted
 - If he lives alone, he can be discharged home with a merocel nasal tampon in situ
 - The following are recognised complications of nasal packing:
 - Septal perforation
 - Aspiration
 - Hypoxia
 - Optic nerve damage
 - Epiphora
 - In surgery for epistaxis:
 - Local anaesthesia can be used for elderly patients
 - Bipolar diathermy is safer
 - The maxillary artery is normally approached endoscopically
 - Removing a septal spur may help
 - Ligation of the external carotid artery is useful as a last resort
 - In the alternative management options for epistaxis:
 - Angiographic embolisation has a similar success rate to arterial ligation
- Hot water irrigation is used for anterior bleeds
 - Patients are normally admitted after endoscopic electrocautery
 - A 0° Hopkin's rod is used in rigid endoscopy
 - Bleeding recurs in 50% of cases when using fibrin glue

Authors' affiliations

L E R Pope, Department of Otolaryngology and Head and Neck Surgery, Addenbrookes Hospital, Cambridge, UK

C G L Hobbs, Department of Otolaryngology and Head and Neck Surgery, St Michael's Hospital, Bristol, UK

Funding: none.

Competing interests: none.

REFERENCES

- Petruson B**, Rudin R. The frequency of epistaxis in a male population sample. *Rhinology* 1975;**13**:129-33.
- Watkinson JC**. Epistaxis. In: Mackay IS, Bull TR, eds. *Scott Brown's otolaryngology*. London: Butterworths, 1997:18/5-7.
- Thaha MA**, Nilssen EL, Holland S, et al. Routine coagulation screening in the management of emergency admission for epistaxis—is it necessary? *J Laryngol Otol* 2000;**114**:38-40.
- Corbridge RJ**, Djazaeri B, Hellier WP, et al. A prospective randomised controlled trial comparing the use of merocel nasal tampons and BIPP in the control of acute epistaxis. *Clin Otolaryngol* 1995;**20**:305-7.
- Holland NJ**, Sandhu GS, Ghufoor K, et al. The Foley catheter in the management of epistaxis. *Int J Clin Pract* 2001;**55**:14-15.
- Schietroma JJ**, Tenzel RR. The effects of cautery on the optic nerve. *Ophthalm Plast Reconstr Surg* 1990;**6**:102-7.
- Green KM**, Board T, O'Keeffe LJ. Oculomotor nerve palsy following submucosal diathermy to the inferior turbinates. *J Laryngol Otol* 2000;**114**:285-6.
- O'Flynn PE**, Shadaba A. Management of posterior epistaxis by endoscopic clipping of the sphenopalatine artery. *Clin Otolaryngol* 2000;**25**:374-7.
- Woolford TJ**, Jones NS. Endoscopic ligation of anterior ethmoidal artery in treatment of epistaxis. *J Laryngol Otol* 2000;**114**:858-60.
- Douglas SA**, Gupta D. Endoscopic assisted external approach anterior ethmoidal artery ligation for the management of epistaxis. *J Laryngol Otol* 2003;**117**:132-3.
- Strong EB**, Bell DA, Johnson LP, et al. Intractable epistaxis: transantral ligation vs. embolization: efficacy review and cost analysis. *Otolaryngol Head Neck Surg* 1995;**113**:674-8.
- Spafford P**, Durham JS. Epistaxis: efficacy of arterial ligation and long-term outcome. *J Otolaryngol* 1992;**21**:252-6.
- Sokoloff J**, Wickbom I, McDonald D, et al. Therapeutic percutaneous embolization in intractable epistaxis. *Radiology* 1974;**111**:285-7.
- Vitek J**. Idiopathic intractable epistaxis: endovascular therapy. *Radiology* 1991;**181**:113-16.
- Tseng EY**, Narducci CA, Willing SJ, et al. Angiographic embolization for epistaxis: a review of 114 cases. *Laryngoscope* 1998;**108**:615-19.
- Vaiman M**, Segal S, Eviatar E. Fibrin glue treatment for epistaxis. *Rhinology* 2002;**40**:88-91.
- Frikart L**, Agrifoglio A. Endoscopic treatment of posterior epistaxis. *Rhinology* 1998;**36**:59-61.
- McGarry GW**. Nasal endoscope in posterior epistaxis: a preliminary evaluation. *J Laryngol Otol* 1991;**105**:428-31.
- Ahmed A**, Woolford TJ. Endoscopic bipolar diathermy in the management of epistaxis: an effective and cost-efficient treatment. *Clin Otolaryngol* 2003;**28**:273-5.
- Shin EJ**, Murr AH. Managing epistaxis. *Curr Opin Otolaryngol Head Neck Surg* 2000;**8**:37-42.
- Stankiewicz JA**. Nasal endoscopy and control of epistaxis. *Curr Opin Otolaryngol Head Neck Surg* 2004;**12**:43-5.
- Burton M**, Doree C. Interventions for recurrent idiopathic epistaxis (nosebleeds) in children. *Cochrane Library*. Issue 1. Oxford: Update Software, 2004.
- Srinivasan V**, Patel H, John DG, et al. Warfarin and epistaxis: should warfarin always be discontinued? *Clin Otolaryngol* 1997;**22**:542-4.
- Tay HL**, Evans JM, McMahon AD, et al. Aspirin, nonsteroidal antiinflammatory drugs, and epistaxis. A regional record linkage case control study. *Ann Otol Rhinol Laryngol* 1998;**107**:671-4.

ANSWERS

1. T, (B) T, (C) F, (D) T, (E) F; 2. F, (B) F, (C) T, (D) F, (E) F; 3. F, (B) T, (C) T, (D) F, (E) T; 4. T, (B) T, (C) F, (D) T, (E) T. 5; T, (B) F, (C) F, (D) T, (E) F.